



ORIGINAL ARTICLE

A Potentially Disastrous Life -Threatening Complication of Emergency Tube Thoracostomy in A Simple Case of Spontaneous Pneumothorax: A Retained Scalpel Blade in The Thorax Cavity

***Nik Ahmad Shaiffudin Nik Him^{1,2}, Nik Arif Nik Mohamad¹, Azizul Fadzli Jusoh¹, Amir Syariffudin², Mohd Adib Aiman²**

¹Faculty of Medicine, Universiti Sultan Zainal Abidin, Jalan Sultan Mahmud, 20400 Kuala Terengganu, Terengganu

²Hospital Pengajar Universiti Sultan Zainal Abidin, Kampus Gong Badak, Kuala Nerus, Terengganu, Terengganu

*Corresponding author: nikshaiffudin@unisza.edu.my

Received: 10/02/2022, Accepted: 20/08/2022, Published: 31/10/2022

Abstract

Emergency tube thoracostomy carries risks of infective and technical complications. The aseptic technique is essential to prevent infections, while blunt dissection method can minimise the associated technical complications. Preparation and adherence to protocols as well as appropriate knowledge and skills, however, are of utmost importance to reduce risks of complications. Physicians must have adequate knowledge of anatomy and the procedure to ensure for accurate site tube placement without any complication. This case illustrates how a failure to appropriately use the instrument resulted in a displaced scalpel blade inside the thoracic cavity. It caused an unnecessary thoracotomy for blade retrieval. The mishap escalated a simple procedure to the potentially disastrous life-threatening event.

Keywords: Emergency tube thoracostomy; complication; pneumothorax; emergency department.

Introduction

Tube thoracostomy is safe and effective. Needle decompression followed by tube thoracostomy is a lifesaving procedure in acute life threatening tension pneumothorax. It is an invasive technique and requires a competent operator who can both ensure correct placement and identify complications associated with the procedure. In several studies, the rate of complications was reported to vary between 4.8% and 30% (Martin et al., 2013; Menger et al., 2012), but the majority of them are preventable.

Complications of tube thoracostomy can be classified as either technical or infective (Ball et al., 2007). Technical complications include tube malposition, blocked drainage, re-expansion pulmonary oedema, subcutaneous emphysema and injuries to cardiac, vascular, and

oesophageal structures. Infective complication comprises empyema, surgical site infections, cellulitis and necrotising fasciitis (Ball et al., 2007). Early detection of complications and establishment of intervention can prevent morbidity and mortality. We illustrate a case of simple, spontaneous pneumothorax turned to be a disastrous complication of emergency tube thoracostomy that leads to unnecessary thoracotomy. This procedure requires adherence to protocols, competence, knowledge and direct supervision to minimise the risk of the complication. Early identification of procedural complication and prompt action necessary to limit the associated morbidity and mortality.

Case Report

A 27-year old man was referred from a general practitioner (GP) for acute shortness of breath for 3-day duration. It was associated with right-sided pleuritic chest pain that was aggravated by a cough. The patient was a chronic active smoker and ectomorph body type with 175 centimeters tall and weighed 52 kilograms.

On arrival at the emergency department (ED), the patient was conscious and alert, able to speak in full sentences and was not in respiratory distress with a respiratory rate of 14 breaths per minute (bpm) and oxygen saturation of 99% under oxygen supplementation 3 liters per minute. Clinical and lung ultrasound suggested a simple pneumothorax on the right lung. Arterial blood gases showed good oxygenation and gas exchange.

Chest radiograph (CXR) confirmed a right pneumothorax, and diagnosis of spontaneous pneumothorax was made. An on call medical resident planned for a right-sided tube thoracostomy insertion, and a junior medical resident performed the procedure using a blunt dissection technique. During the process, the junior medical resident encountered difficulties when he was unable to reach a pleural cavity. After 10 minutes of difficulties, his senior medical resident was called and took over the procedure. He successfully inserted the tube through the opening done by the intern. The tube was functioning well.

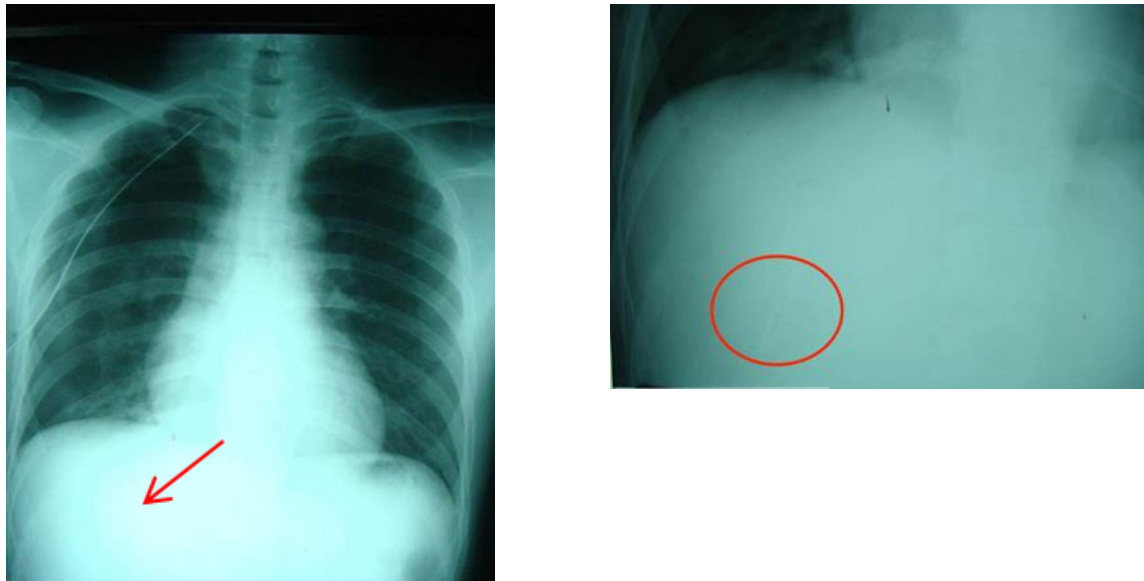


Figure 1. CXR PA view showed a chest tube with right pneumothorax and scalpel blade in-situ

During post procedure instrument count, a scrub nurse noted a missing scalpel blade from its holder. A digital blind local exploration of the insertion site was attempted but failed. An urgent

CXR revealed a scalpel blade located deep near the right diaphragm (Figure 1). The scalpel blade was further localized using computed tomography (CT) of thorax (Figure 2).

The patient underwent a right posterolateral thoracotomy via the 6th intercostal spaces for blade recovery. Intraoperative findings included the thoracostomy tube in the pleural cavity, the presence of apical bullae on the right lung and 50 ml of blood collection in the right hemithorax. The blade found at the posterior diaphragmatic recess. Postoperatively, the patient's required another thoracostomy tube insertion on the same side as he developed expanding pneumothorax. The chest tube removed on day ninth post operation and he was discharged well on day thirteenth.

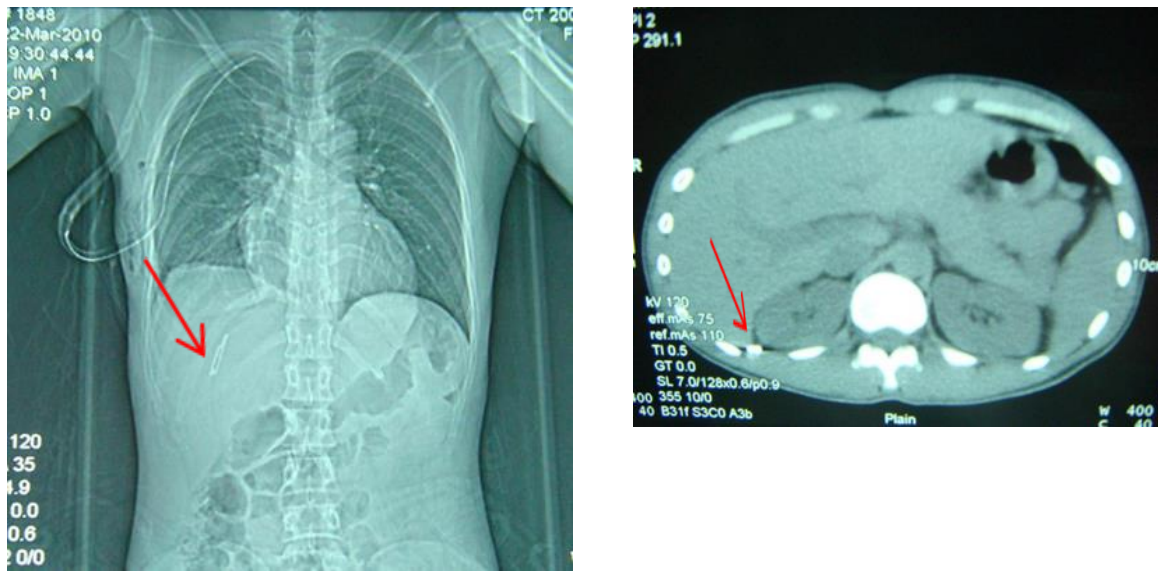


Figure 2. Plain CT thorax showed scalpel blade location

Results and Discussion

Tube thoracotomy complications in Emergency Departments (ED) can reach up to 40% due to its unpropitious environment (Ball et al., 2007; Hernandez et al., 2018). Tube malposition is the most frequent complication in ED (Kwiatt et al., 2014; Hernandez et al., 2018). The trocar technique showed higher risk of tube malposition compared to blunt dissection technique (Kwiatt et al., 2014). Higher complication rates have been found in a critically ill patient (Aylwin et al., 2008). In emergency situations, it is imperative that procedures follow strict protocols leaving no room for trial and error. This case highlights how a simple negligence has resulted in significant morbidity and potential mortality.

The safety triangle is a safe site for tube thoracostomy insertion, and knowledge of the anatomy of the thorax can help avoiding technical complications. Physicians are trained to perform finger sweeps within the thoracic cavity to detect if the lung is adherent to the chest wall. This technique is useful for tube placement to help position the tube on the superior rib margin to avoid injuring the inferior intercostal neurovascular bundle. Unfortunately, a survey of junior residents on the anatomical landmarks for inserting an intercostal drain revealed that 45% failed to locate the safe area and the most common error was an insertion at a site lower to the recommended area (Kesieme et al., 2012). Even with correct techniques, complication rates can approach up to 30% (Martin et al., 2013; Menger et al., 2012). Retained swab and instrument (RSI) post-operative is recognized medical negligence and lead to catastrophic implication for patients and healthcare providers (HCP). The literature reports an estimated 1:1000 to 1:1500 intra-abdominal surgeries

result in a RSI (Gawande, Studdert, Orav, Brennan, & Zinner, 2003; Hempel et al., 2015). In a systematic review study, the median incidence estimate for RSI was 1.32 events per 10000 surgical procedures (Hempel et al., 2015). However, the magnitude of the problem is most likely underestimated because of the reluctance on the part of clinicians and hospitals to disclose these types of errors (Zarenezhad et al., 2017). Alertness among HCP involved in the procedure is paramount to prevent the unnecessary complication. Recent prospective multi-center trials showed the efficacy of new technologies aiding manual counting in reducing the incidence of RSI (Gawande et al., 2003; Lincourt et al., 2007). The risk factors for RSI were an emergency procedure, high body mass index, unexpected change in operation (Gawande et al., 2003), number of major procedure performed and incorrect counts recorded (Lincourt et al., 2007). Based on two retrospective case-control studies, the outcome of the RSI includes death, readmission, reoperation, sepsis and perforation of viscus and internal organ (Gawande et al., 2003; Lincourt et al., 2007). Therefore, direct supervision by senior medical personnel and strict adherence to protocols are mandatory to avoid both technical and infection complications associated with emergency tube thoracostomy.

As illustrated in this case, early identification of complication is necessary to limit the associated morbidity and mortality. Both the patient and equipment must be examined during and after the procedure. Upon identification of complications of tube thoracotomy insertions, an emergency HCP should inform and consult senior colleagues. They should not be allowed to explore the wound on their own to avoid further harms. This case illustrated how a non-supervised emergency tube thoracotomy resulted in unnecessary operative thoracotomy emphasizing the importance of direct supervision before, during and after the procedure.

Conclusion

Emergency tube thoracostomy in ED carries a higher complication risk as it performed under the sub-optimal and urgent situation. It demands an adherence to protocols and equip with a practical knowledge otherwise direct supervision is required. This case illustrates how a failure of proper handling of instrument caused significant morbidity and a life-threatening situation.

Acknowledgement

We would like to thank to Prof Rusli Ismail for the idea of the manuscript writing and former Head of Emergency & Trauma Department, Hospital Sultanah Nur Zahirah for the help in writing the case report. Not forgetting the dean of Faculty Medicine for the encouragement of manuscript writing.

Disclosure of Interest

The authors declare that they have no conflict of interest concerning this article.

References

- Aylwin, C. J., Brohi, K., Davies, G. D., & Walsh, M. S. (2008). Pre-Hospital and In-Hospital Thoracostomy: Indications and Complications. *Ann R Coll Surg Engl*, 90(1), 54-57. doi:10.1308/003588408x242286
- Ball, C. G., Lord, J., Laupland, K. B., Gmora, S., Mulloy, R. H., Ng, A. K., Kirkpatrick, A. W. (2007). *Chest*

tube complications: how well are we training our residents? *Can J Surg*, 50(6), 450-458.

Hernandez MC, El Khatib M, Prokop L, Zielinski MD, Aho JM (2018). Complications in tube thoracostomy: Systematic review and meta-analysis. *J Trauma Acute Care Surg*. 85(2):410-416.

Gawande, A. A., Studdert, D. M., Orav, E. J., Brennan, T. A., & Zinner, M. J. (2003). Risk factors for retained instruments and sponges after surgery. *N Engl J Med*, 348(3), 229-235.

Hempel, S., Maggard-Gibbons, M., Nguyen, D. K., Dawes, A. J., Miake-Lye, I., Beroes, J. M., Shekelle, P. G. (2015). Wrong-Site Surgery, Retained Surgical Items, and Surgical Fires: A Systematic Review of Surgical Never Events. *JAMA Surg*, 150(8), 796-805.

Kesieme, E. B., Dongo, A., Ezemba, N., Irekpita, E., Jebbin, N., & Kesieme, C. (2012). Tube thoracostomy: complications and its management. *Pulm Med*, 2012, 256878.

Kwiatt, M., Tarbox, A., Seamon, M. J., Swaroop, M., Cipolla, J., Allen, C., Stawicki, S. P. (2014). Thoracostomy tubes: A comprehensive review of complications and related topics. *Int J Crit Illn Inj Sci*, 4(2), 143-155.

Lincourt, A. E., Harrell, A., Cristiano, J., Sechrist, C., Kercher, K., & Heniford, B. T. (2007). Retained foreign bodies after surgery. *J Surg Res*, 138(2), 170-174.

Martin, M., Schall, C. T., Anderson, C., Kopari, N., Davis, A. T., Stevens, P., Mosher, B. D. (2013). Results of a clinical practice algorithm for the management of thoracostomy tubes placed for traumatic mechanism. *SpringerPlus*, 2(1), 642.

Menger, R., Telford, G., Kim, P., Bergey, M. R., Foreman, J., Sarani, B., Sims, C. A. (2012). Complications following thoracic trauma managed with tube thoracostomy. *Injury*, 43(1), 46-50.

Zarenezhad, M., Gholamzadeh, S., Hedjazi, A., Soltani, K., Gharehdaghi, J., Ghadipasha, M., Zare, A. (2017). Three years evaluation of retained foreign bodies after surgery in Iran. *Annals of Medicine and Surgery*, 15, 22-25.

How to cite this paper:

Nik Ahmad Shaiffudin Nik Him, Nik Arif Nik Mohamad, Azizul Fadzli Jusoh, Amir Syariffudin, Mohd Adib Aiman (2022). A Potentially Disastrous Life -Threatening Complication of Emergency Tube Thoracostomy in A Simple Case of Spontaneous Pneumothorax: A Retained Scalpel Blade in The Thorax Cavity. *Malaysian Journal of Applied Sciences*, 7(2), 24-28.